
Central neurocytoma of atypical behavior. Case report and literature review

Neurocitoma central de comportamento atípico. Relato de caso e revisão de literatura

Received: 20-05-2024 | Accepted: 23-06-2024 | Published: 26-06-2024

Keyci Shizue Ito Tabata

ORCID: <https://orcid.org/0009-0005-5424-8333X>

Evangelical University of Goiás (UniEVANGÉLICA), Anápolis (GO), Brazil
Gastromed – Clínica de Gastroenterologia e Medicina Avançada

Flávio Vecchi Barbosa Júnior

ORCID: <https://orcid.org/0009-0007-6434-5437>

Evangelical University of Goiás (UniEVANGÉLICA), Anápolis (GO), Brazil
Gastromed – Clínica de Gastroenterologia e Medicina Avançada

Fernanda N. B. R. Alves

ORCID: <https://orcid.org/0009-0004-3623-0366>

Evangelical University of Goiás (UniEVANGÉLICA), Anápolis (GO), Brazil
Gastromed – Clínica de Gastroenterologia e Medicina Avançada

Wilson Jose Sena Pedro

ORCID: <https://orcid.org/0009-0008-0192-3292>

Evangelical University of Goiás (UniEVANGÉLICA), Anápolis (GO), Brazil
Gastromed – Clínica de Gastroenterologia e Medicina Avançada

Lenita Vieira Braga

ORCID: <https://orcid.org/0009-0001-0479-0543>

Evangelical University of Goiás (UniEVANGÉLICA), Anápolis (GO), Brazil
Gastromed – Clínica de Gastroenterologia e Medicina Avançada

Larissa Rodrigues Alves

ORCID: <https://orcid.org/0009-0002-2333-7362>

Medicine Course, Evangelical University of Goiás (UniEVANGÉLICA), Anápolis (GO), Brazil
Gastromed – Clínica de Gastroenterologia e Medicina Avançada

Miriã Cândida Oliveira

ORCID: <https://orcid.org/0000-0002-5302-1388>

Evangelical University of Goiás (UniEVANGÉLICA), Anápolis (GO), Brazil

João Pedro R. Afonso

ORCID: <https://orcid.org/0000-0002-1392-4910>

Evangelical University of Goiás (UniEVANGÉLICA), Anápolis (GO), Brazil
E-mail: joaopedro180599@gmail.com

Luis Vicente Franco Oliveira

ORCID: <https://orcid.org/0009-0007-6434-5437>

Evangelical University of Goiás (UniEVANGÉLICA), Anápolis (GO), Brazil
E-mail: oliveira.lvf@gmail.com

Deise A. A. P. Oliveira

ORCID: <https://orcid.org/0000-0002-5765-1897>

Evangelical University of Goiás (UniEVANGÉLICA), Anápolis (GO), Brazil

ABSTRACT

Central neurocytomas are tumors of the central nervous system (CNS) that typically show benign behavior and progression. These tumors usually occur in the lateral ventricles of young individuals. We present the case of a 36-year-old male patient who presented with an intraventricular expansive lesion causing hydrocephalus and seizures. The patient underwent an incomplete resection of the lesion, but developed persistent postoperative hydrocephalus, requiring a ventriculoperitoneal shunt. The progression was favorable, and the patient was discharged for outpatient follow-up. Anatomic pathology examination revealed central neurocytoma, confirmed through immunohistochemistry. The objective of this report is to present a case of this rare neoplasm, review the literature, and highlight its significance given the favorable prognosis.

Keywords: Central Neurocytoma; Central Nervous System Tumor; Hydrocephalus; Radiotherapy.

RESUMO

Os neurocitomas centrais são tumores do sistema nervoso central (SNC) que normalmente apresentam comportamento e progressão benignos. Esses tumores geralmente ocorrem nos ventrículos laterais de indivíduos jovens. Apresentamos o caso de um paciente do sexo masculino, 36 anos, que apresentou lesão expansiva intraventricular causando hidrocefalia e convulsões. O paciente foi submetido à ressecção incompleta da lesão, mas evoluiu com hidrocefalia pós-operatória persistente, necessitando de derivação ventriculoperitoneal. A evolução foi favorável e o paciente recebeu alta para acompanhamento ambulatorial. O exame anatomopatológico revelou neurocitoma central, confirmado por imunohistoquímica. O objetivo deste relato é apresentar um caso desta neoplasia rara, revisar a literatura e destacar sua importância dado o prognóstico favorável.

Palavras-chave: Neurocitoma Central; Tumor do Sistema Nervoso Central; Hidrocefalia; Radioterapia.

INTRODUCTION

Central neurocytomas are rare CNS tumors that commonly localize in the lateral ventricles of young adults. These tumors generally exhibit benign behavior, but approximately 20% of cases are associated with a worse prognosis, displaying anaplastic characteristics and increased cellular proliferation. Such anaplastic tumors show distinct biological behavior, and are termed atypical central neurocytomas. Imaging of these tumors is characteristic, as well as their histopathology. The current treatment of choice for neurocytomas is neurosurgical resection. This study describes a case of central neurocytoma treated at the Oncology Unit of Anápolis, part of the Cancer Combat Association of Goiás (ACCG-Goiás), and reviews the main features, diagnosis, and treatment of these rare brain tumors.

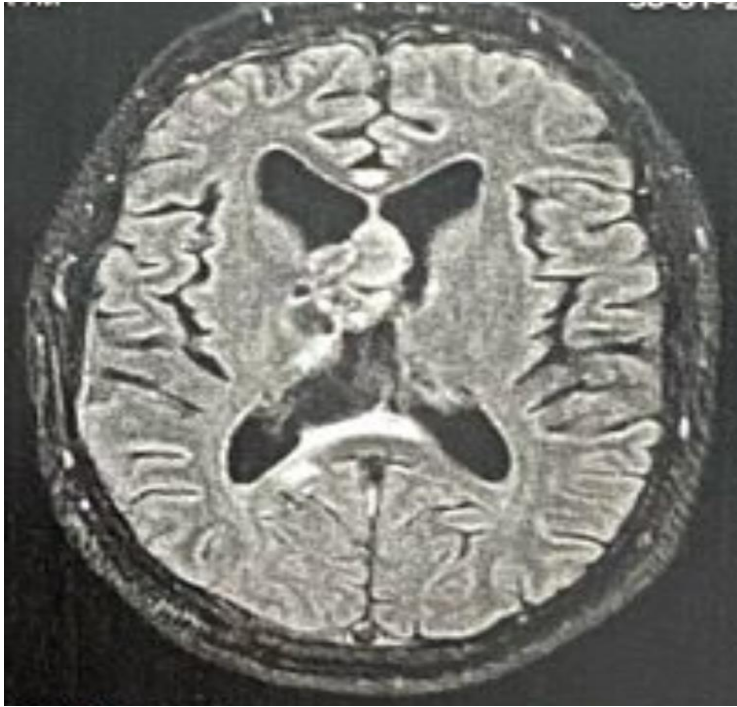
CASE REPORT

A.C.S., a 36-year-old married white male, was referred to the radio-oncology service of the Oncology Unit of Anápolis (Cancer Combat Association of Goiás) on January 9, 2024, for stereotactic radiotherapy treatment of a brain tumor. He reported that two years ago he began experiencing seizures, episodes of mental confusion, and ataxia. He was referred to the neurology department where a brain tumor was diagnosed following a cranial MRI (figs.1 and 2).

Figure 1 – Expansive, heterogeneous lesion located in the anterior portion of the lateral ventricles, connected to the foramina of Monro, extending to the third ventricle, with characteristics of a neoplastic lesion.

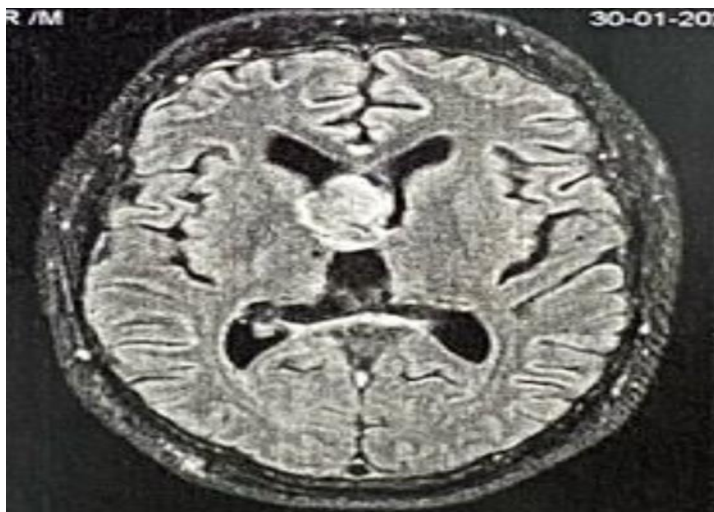

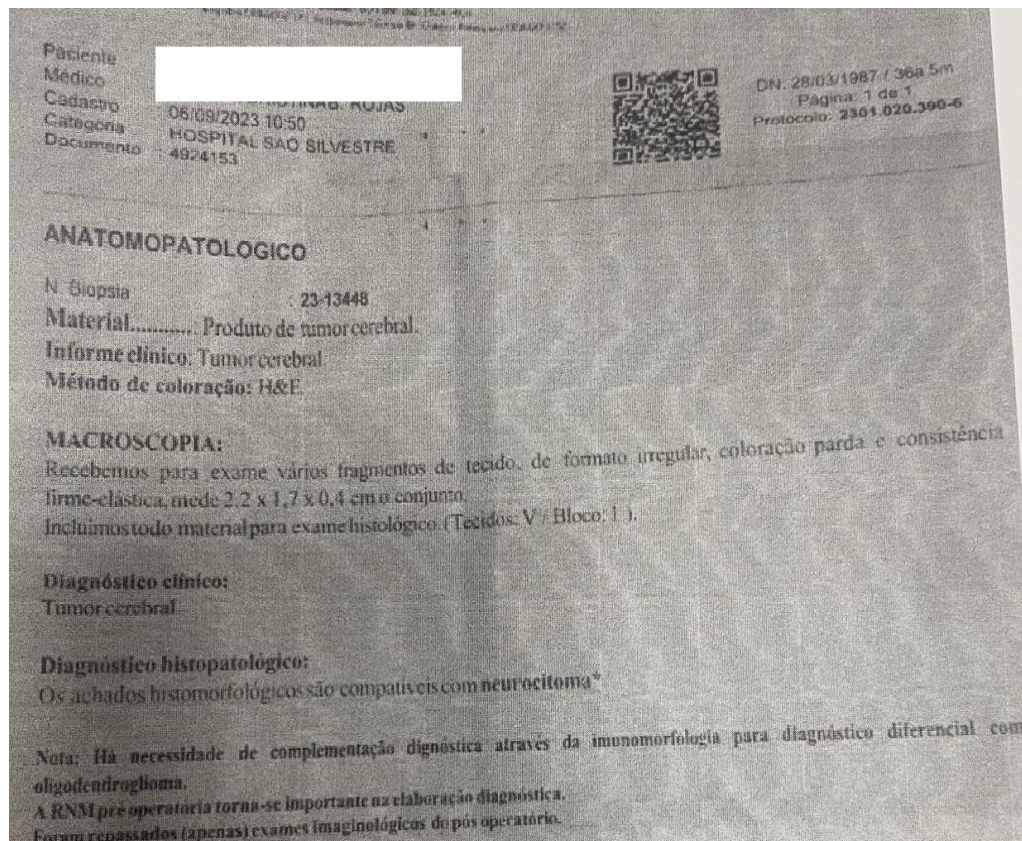Figure 2 – Expansive lesion measuring 4.0 x 2.4 x 2.3 cm in lateral ventricles with heterogeneous post-contrast enhancement.



Following the brain tumor diagnosis, treatment with anticonvulsants was started, and the patient underwent neurosurgery to attempt removal of the tumor. The surgical technique consisted of microsurgical resection of the tumor with a transcortical approach to the left lateral ventricle via the superior frontal sulcus. The lesion had adhered to the ventricular walls and was partially resected. The procedure was uneventful.

Postoperatively, the patient presented with high sustained intracranial pressure (caused by hydrocephalus), and ventriculoperitoneal shunting was performed. Following the procedure, the patient had a favorable recovery and was discharged with instructions to return for outpatient follow-up. Biopsy results are shown in figure 3 below.

Figure 3: Biopsy of brain tumor confirming the histological finding of neurocytoma.



The anatomic pathology study of the surgical specimen identified a tumor with proliferation of small, round, cohesive, isomorphic and diffuse cells, with signs of previous hemorrhage. Immunoreactivity indicated central neurocytoma.

Additionally, immunohistochemistry showed positivity for GD56 (123C3), synaptophysin (DAK-SYNAP), and Ki67 (MIB1), and negativity for CD99 and neurofilament 2F11. The study was performed using the Hier-Ptlink antigen retrieval technique. The described characteristics are consistent with central neurocytoma, and the Ki67 positivity in approximately 5% of the cells allows the neoplasm to be subclassified as atypical central neurocytoma (fig. 4).

Figure 4: immunohistochemistry of neurocytoma showing the antibody panel – atypical neurocytoma of the central nervous system.

Exame: Estudo Imuno-histoquímico

Referência do patologista/médico: Dr. Wanderley Ribeiro Borges de Figueiredo.

Material recebido: Tumor cerebral AP: 13448/23 IH: 2452/23.

Motivo do estudo Imuno-histoquímico: Pesquisa de células ganglionares.

Hipótese diagnóstica: Oligodendroglioma?

Tempo de fixação da amostra: Não informado. Material externo.

Relatório Imuno-histoquímico: Espécime submetido à estudo Imuno-histoquímico automatizado com recuperação antigênica Hier Pluslink, incubação/revelação em Autostainer Link 48 Dako e/ou Dako Omnis.

Painel de anticorpos	Resultado
1. Proteína Glial Fibril Ácida (Policlonal)	Negativo.
2. Neurofilamento (2F11)	Negativo.
3. CD56 (123C3)	Positivo.
4. Sinaptofisina (DAK-SYNAP)	Positivo.
5. Ki67 (MIB1)	Positivo, 1,0%.
6. CD99 (12E7)	Negativo.

Observação: Controles internos e externos das respectivas reações atestam a fidelidade das amostras.

DIAGNÓSTICO:

Perfil imuno-histoquímico revela proliferação de células pequenas arredondas, coesas, isomórficas, difusas, com sinais de hemorragia antiga, cujo padrão imunorreativo é indicativo de neurocitoma central.

Post-surgery, as the tumor had not been completely resected, the patient was referred for radiotherapy treatment to attempt to stabilize or even reduce tumor size, allowing for potential new surgical approach. Following radiotherapy treatment, the patient remains clinically stable, on anticonvulsants, and under outpatient follow-up. The tumor remains stable, without growth, and the patient awaits possible new surgical treatment.

DISCUSSION

Central neurocytomas are uncommon CNS tumors. They typically affect the lateral ventricles of young patients, usually around the third decade of life (FIGARELLA-BRANGER et al., 1992; FIGARELLA-BRANGER et al., 2000). In 1982, Hassoun et al. (3) characterized the disease as a rare brain neoplasm. Even today, few cases of neurocytomas have been reported (RADES; FEHLAUER, 2002). The incidence of this tumor is extremely low, accounting for about 0.1 to 0.5% of all brain tumors (KIM et al., 1997; DODERO et al., 2000). There is no gender distribution difference, with a male-to-female occurrence ratio of 1.02 to 1 (HASSOUN et al., 1993). Neurocytoma brain tumors can be classified into two groups: atypical neurocytomas, which have a higher potential for severity due to the presence of anaplasia, and typical neurocytomas, which exhibit a more benign behavior and are more likely to be completely resected. Typical neurocytomas, due to their low degree of anaplasia, are more easily resected and have a better prognosis. They also exhibit slower growth, although they can occupy the lateral ventricle and cause symptoms of intracranial hypertension (RADES et al., 2005). The other type, atypical neurocytoma, occurs in 20% of cases. These tumors have a worse prognosis because they grow faster and have a higher degree of anaplastic cells. Atypical neurocytomas are more difficult to resect due to their greater invasive capacity compared to typical neurocytomas. Histologically, they show more necrosis, endothelial proliferation, cellular pleomorphism, and mitotic activity (HASSOUN et al., 1993; KIM et al., 1996). Tumors with a worse prognosis are also characterized by the presence of markers such as Ki67 (an antigen that reacts with monoclonal antibodies MIB-1) in immunohistochemistry, as these are associated with increased local recurrence and mortality.

Tumors with MIB-1 (MIB-1 LI) > 2% also have a worse prognosis. They have a higher rate of locoregional recurrence and lower five-year disease-free survival rates (SÖYLEMEZOGLU et al., 1997; SCHMIDT et al., 2004).

As shown in this case report, the clinical course of the disease is usually slow, with symptoms such as headaches, seizures, or visual changes. The initial presentation of the tumor may involve extrinsic compression of the optic chiasm or even obstruction of the cerebrospinal fluid circulation system, leading to symptoms of hydrocephalus

(HASSOUN et al., 1993; BRAT et al., 2001). Symptoms related to intracranial hypertension are common due to obstruction of the foramen of Monro, which was notably observed in this case report.

In the vast majority of cases, central neurocytomas are located in the ventricular system (HASSOUN et al., 1993; STEPHAN et al., 1999). It is important to emphasize once again that the initial presentation in the case cited here was due to symptoms arising from obstruction of the cerebrospinal fluid flow in the patient's central nervous system, causing a true mass effect and leading to symptoms such as the seizures and headaches mentioned by the patient. Another significant point is that central neurocytomas often adhere to the walls of the cerebral ventricles (CHEN et al., 2008), which sometimes makes total tumor resection impossible. In the patient from the case cited here, the neurocytoma was not completely resected because it was adhered to its wall, significantly complicating the surgical management. Neurocytomas can also be found, less frequently, in the third ventricle (MAJÓŠ; COLL; PONS, 1997), fourth ventricle (HSU et al., 2002), and, rarely, in the spinal cord (STEPHAN et al., 1999).

Imaging exams are crucial for diagnosing central neurocytoma and differentiating it from other brain neoplasms and central nervous system infections as well. On CT scans, central neurocytomas typically appear as solitary masses that are isointense in the lateral ventricles, near the foramen of Monro (CHEN et al., 2008). The image shows uniform contrast enhancement (SHARMA et al., 2006), and calcifications are evident in approximately 51% of cases (HASSOUN et al., 1993). MRI reveals isointense images on T1 and T2, compared to the cerebral cortex (RADES; SCHILD, 2006), with strong gadolinium enhancement (SHARMA et al., 1999).

When resected, neurocytomas exhibit macroscopic characteristics. They are usually grayish, lobulated masses. Cystic areas or regions of necrosis (CHEN et al., 2008), and even local hemorrhage areas (SHARMA et al., 2006), can be present.

Histopathologically, central neurocytomas are well-differentiated tumors with small, uniform cells, rounded nuclei, and scant cytoplasm, arranged in a perinuclear halo, resembling an oligodendroglioma. Sparse mitotic activity and the presence of

cellular areas alternating with fibrillar regions containing irregular rosette-like structures are microscopic features that suggest central neurocytoma (SHARMA et al., 1999). Scattered blood vessels can be observed throughout the sample, and areas of calcification are seen in half of the biopsies (FIGARELLA-BRANGER et al., 2000). The presence of necrosis, intense mitotic activity, and vascular proliferation are indicators of a worse prognosis in atypical lesions (RADES; SCHILD, 2006).

Immunohistochemical analysis notably confirms the neuronal origin of the neoplasms, as they test positive for neuron-specific enolase and synaptophysin (HASSOUN et al., 1993; CHEN et al., 2008). Positivity for neuronal nuclear antigen (NeuN) can be useful in cases where the synaptophysin test results are ambiguous (BRAT et al., 2001; SÖYLEMEZOGLU et al., 2003). Positivity for GFAP is variable in central neurocytomas (SCHMIDT et al., 2004) and may suggest a more guarded prognosis (ELEK et al., 1999). Immunohistochemistry is also valuable for assessing the proliferative potential of the neoplasm, especially in association with anaplastic characteristics. The latter correlates the tumor with less favorable outcomes (MACKENZIE, 1999; SÖYLEMEZOGLU et al., 1997).

The large majority of studies report that the treatment of choice for central neurocytoma is neurosurgical resection (FIGARELLA-BRANGER et al., 1999; RADES; FEHLAUER, 2002; KIM et al., 1997; YASARGIL et al., 1992). There is currently no effective chemotherapeutic treatment, and radiotherapy should be reserved for cases where the tumors cannot be completely resected or when the tumors cannot be removed due to their close anatomical relationship with critical structures that cannot be damaged.

Several scientific articles have discussed the use of radiotherapy following both total and incomplete resection. Rades and Schild (RADES; SCHILD, 2006) reviewed data from 351 patients diagnosed with typical central neurocytoma and showed that 10-year survival was higher for patients with total resection than those with incomplete resection (100% vs. 90%, respectively). The same study evaluated 87 patients with atypical central neurocytoma and found higher mortality compared to typical neurocytoma patients (22% vs. 3%, with median survival of 17 vs. 16 months,

respectively). Likewise, total resection was associated with better 5-year survival than incomplete resection (91% vs. 46%, respectively). Postoperative radiotherapy apparently benefited only patients with incomplete resection, not those with total resection. A similar study by Rades and Fehlaue (2002), which included data from 310 patients across 91 institutions, evaluated the survival of patients who underwent surgical treatment for central neurocytoma. The five-year survival rate for the group that had total resection was 99%, while it was 86% for the group that had incomplete resection. As in the previous study, radiotherapy only benefited patients with incomplete resection. There is still limited evidence on the effects of chemotherapy and radiosurgery in the management of this neoplasm (BRANDES et al., 2000; ANDERSON et al., 2001), and more studies are needed to determine the outcomes with these therapeutic modalities.

FINAL CONSIDERATIONS

Central neurocytoma is a rare neoplasm that usually has a good prognosis. It should be suspected mainly in younger patients and has typical characteristics on imaging exams. Confirmation is via histological and immunohistochemical examination, which can help define tumor aggressiveness and prognosis. The current treatment of choice is total lesion resection, but when only incomplete resection is possible, complementary radiotherapy is recommended.

REFERENCES

- ANDERSON, R.C. et al. Radiosurgery for the treatment of recurrent central neurocytomas. *Neurosurgery*, v. 48, p. 1231-7, 2001.
- BRANDES, A.A. et al. Chemotherapy in patients with recurrent and progressive central neurocytoma. *Cancer*, v. 88, p. 169-74, 2000.
- BRAT, D.J. et al. Extraventricular neurocytomas. Pathologic features and clinical outcome. *Am J Surg Pathol*, v. 25, p. 1252-60, 2001.
- CHEN, C.L. et al. Central neurocytoma: A clinical, radiological and pathological study of nine cases. *Clin Neurol Neurosurg*, v. 110, p. 129-36, 2008.
- DODERO, F. et al. Central neurocytoma: 2 case reports and review of the literature. *Acta Neurochir (Wien)*, v. 142, p. 1417-22, 2000.
- ELEK, G. et al. Central neurocytoma with malignant course. Neuronal and glial differentiation and craniospinal dissemination. *Pathol Oncol Res*, v. 5, p. 155-9, 1999.
- FIGARELLA-BRANGER, D. et al. Central neurocytoma: critical evaluation of a small cell neuronal tumor. *Am J Surg Pathol*, v. 16, p. 97-109, 1992.
- FIGARELLA-BRANGER, D.; SOYLEMEZOGLU, F.; KLEIHUES, P.; HASSOUN, J. Central neurocytoma. In: KLEIHUES, P.; CAVENEE, W.K., (eds.) *Pathology and genetics of tumors of the nervous system*. Lyon: IARC Press, p. 107-9, 2000.
- HASSOUN, J. et al. Central neurocytoma. An electronmicroscopic study of two cases. *Acta Neuropathol*, v. 56, p. 151-6, 1982.
- HASSOUN, J. et al. Central neurocytoma: a synopsis of clinical and histological features. *Brain Pathol*, v. 3, p. 297-306, 1993.
- HSU, P.W. et al. Fourth ventricle central neurocytoma: case report. *Neurosurgery*, v. 50, p. 1365-7, 2002.
- KIM, D.G. et al. Central neurocytoma: proliferative potential and biological behavior. *J Neurosurg*, v. 84, p. 742-7, 1996.
- KIM, D.G. et al. Central neurocytoma: the role of radiation therapy and long term outcome. *Cancer*, v. 79, p. 1995-2002, 1997.
- MACKENZIE, I.R. Central neurocytoma: histologic atypia, proliferation potential, and clinical outcome. *Cancer*, v. 85, p. 1606-10, 1999.
- MAJÓŠ, C.; COLL, S.; PONS, L.C. Central neurocytoma arising in the third ventricle. *Neuroradiology*, v. 39, p. 270-2, 1997.
- RADES, D. et al. Well differentiated neurocytoma: what is the best available treatment? *Neuro Oncol*, v. 7, p. 77-83, 2005.

RADES, D.; FEHLAUER, F. Treatment options for central neurocytoma. *Neurology*, v. 59, p. 1268-70, 2002.

RADES, D.; SCHILD, S.E. Treatment recommendations for the various subgroups of neurocytomas. *J Neurooncol*, v. 77, p. 305-9, 2006.

SCHMIDT, M.H. et al. Central neurocytoma: a review. *J Neurooncol*, v. 66, p. 377-84, 2004.

SHARMA, M.C. et al. Intraventricular neurocytoma: a clinicopathological study of 20 cases with review of the literature. *J Clin Neurosci*, v. 6, p. 319-23, 1999.

SHARMA, M.C. et al. Neurocytoma: a comprehensive review. *Neurosurg Rev*, v. 29, p. 270-85, 2006.

SÖYLEMEZOGLU, F. et al. Atypical central neurocytoma. *J Neuropathol Exp Neurol*, v. 56, p. 551-6, 1997.

SÖYLEMEZOGLU, F. et al. Neuronal nuclear antigen (NeuN): a new tool in the diagnosis of central neurocytoma. *Pathol Res Pract*, v. 199, p. 463-8, 2003.

STEPHAN, C.L. et al. Neurocytoma of the cauda equina. Case report. *J Neurosurg*, v. 90, p. 247-51, 1999.

YASARGIL, M.G. et al. Central neurocytoma: histopathological variants and therapeutic approaches. *J Neurosurg*, v. 76, p. 32-7, 1992.